

A possible new mutation to the *Mmp14* gene

Michelle M. Curtain, Leah Rae Donahue

Source of Support: NIH-NEI grant EY015073 to Leah Rae Donahue

Mutation (allele) Symbol: *sabe*

Mutation (allele) Name: Small and Bugged-Eyed

Strain of Origin: C57BL/6J

Current Strain Name: B6(129P2)-*sabe*/J

Stock #007710 (jaxmice.jax.org)

Phenotype Categories: craniofacial, skeletal, size, deafness, eye, movement anomalies, homozygous lethality

Origin and description

We report a spontaneous autosomal recessive mutation that arose in a research lab at The Jackson Laboratory in 2006. Homozygotes have significantly smaller bodies along with rounded skulls and large eyes (see photo on allele detail page). At about two weeks old, homozygotes start to look smaller than control littermates and they never grow after three weeks old. In fact, mutants that survive seem to slowly waste away as they get skinnier over time. Overall, they have significantly shorter life spans ranging from three weeks to three months with some mutants living longer. As they age, their gait becomes stiff. *sabe* arose spontaneously on a C57BL/6J background and was accidentally crossed to a C57BL/6J congenic strain bearing a 129P2-derived gene trap that has since been bred out of this *sabe*-bearing subline. *sabe* homozygotes do not breed. The colony is maintained by progeny testing to identify carriers, or by ovarian transplant on a female *sabe/sabe*.

The ovaries are transplanted into a C3SnSmn.CB17-*Prkdc*^{scid}/J (stock # 001131) host, and then the host is mated to a +/- or *sabe*/+ male.

Genetic analysis

The *sabe* mutation was proven to be recessive by mating a C57BL/6J female to a *sabe*/+ male. There were no affected offspring in the first generation (0/5). After intercrossing the F1s, mutants arose in the second generation (2/17). The strain was mapped by doing ovarian transplant surgery on a female homozygote. The host C3SnSmn.CB17-*Prkdc*^{scid}/J female was then mated to an inbred CAST/Ei male. F1 mice from this breeding were intercrossed and DNA was collected from F2 mutants. Using our standard mapping protocol spleen and tail tips were collected and stored at -70 degrees C. DNA was extracted from either spleen or tail tips using standard phenol extraction methods. Polymerase chain reaction was done with MIT or Research Genetics primer pairs (MapPairs, from Research Genetics, Huntsville, Ala., or from Integrated DNA Technologies, Coralville, Ia.)

Scoring 11 mice representing 22 meioses, *sabe* maps to Chromosome 14 between *D14MIT253* and *D14MIT234* or from 23.8 Mb to 58.6 Mb. A candidate gene, *Mmp14*, is

located at 55 Mb. *Mmp14* null mice exhibit craniofacial dysmorphism, arthritis, osteopenia, dwarfism, fibrosis of soft tissue, reduced bone formation, pulmonary hypoplasia, and impaired alveologenesi. Mice homozygous for the *sabe* mutation exhibit many of the same characteristics as *Mmp14* null mice and are discussed in the Biological Characterization.

Biological Characterization

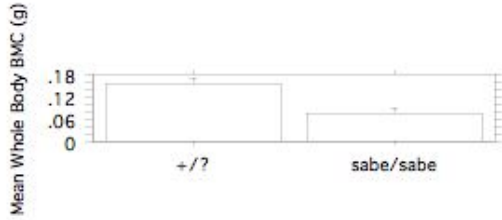
A. DEXA analysis of aBMD and Body Composition Four-week-old *sabe/sabe* and +/- male mice were collected for whole body, areal bone mineral density (aBMD), bone mineral content (BMC) and body composition (lean, fat and % fat mass) to be assessed by PIXImus densitometry¹.

Table 1: PIXImus Densitometric Measurements of Four-Week-Old *sabe* Mutant and Control Mice (n=6; mean ± SEM;^ap ≤ 0.05)

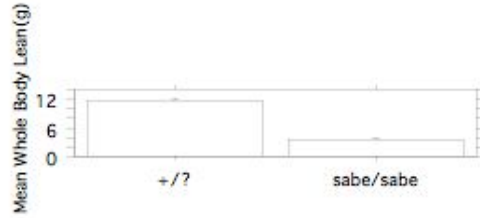
Measurements	Male <i>sabe/sabe</i>	Male +/-
Whole Body BMD (g/cm ²)	0.0257± 0.00119	0.0283 ± 0.00084
Whole Body BMC (g)	0.077 ± 0.0120 ^a	0.158 ± 0.0147
Whole Body Fat (g)	0.8 ± 0.07 ^a	1.9 ± 0.14
Whole Body Lean (g)	3.4 ± 0.31 ^a	11.5 ± 0.49
% Fat	18 ^a	14
Total Mass (g)	4.2 ± 0.36 ^a	13.4 ± 0.53
Skull BMD (g/cm ²)	0.0622 ± 0.00254 ^a	0.0750 ± 0.00131
Skull BMC (g)	0.079 ± 0.0060 ^a	0.143 ± 0.0045
Skull BMD/Body BMD	2.4262 ± 0.05881 ^a	2.6616 ± 0.04257

Mutants had significantly less whole body BMC, lean, total mass, skull BMD, skull BMC and skull to body BMD ratio compared to controls. Mutants also had significantly less body fat having about half the grams of fat than controls; but mutants had significantly more percent fat than controls since fat constituted 18 percent of their total body mass compare to 14% in controls.

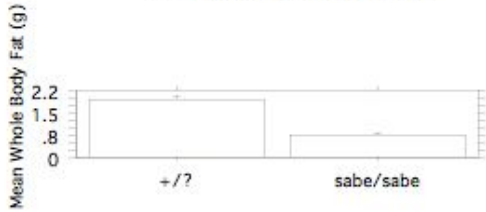
4 Week B6(129P2)-*sabe*/J
 Whole Body BMC (g)
 Split by Sex
 (n=6;mean ± SEM;p≤0.05)



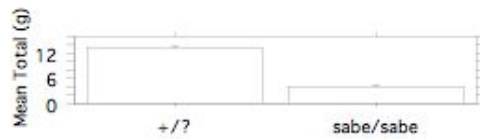
4 Week B6(129P2)-*sabe*/J
 Whole Body Lean (g)
 Split by Sex
 (n=6;mean ± SEM;p≤0.05)



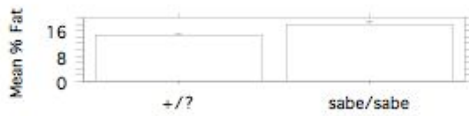
4 Week B6(129P2)-*sabe*/J
 Whole Body Fat (g)
 Split by Sex
 (n=6;mean ± SEM;p≤0.05)



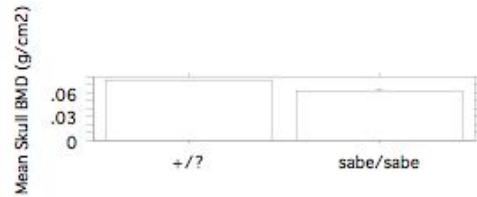
4 Week B6(129P2)-*sabe*/J
 Whole Body Total (g)
 Split by Sex
 (n=6;mean ± SEM;p≤0.05)



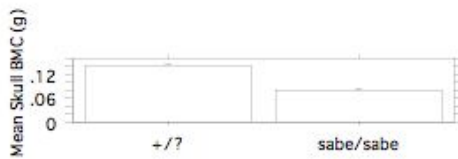4 Week B6(129P2)-*sabe*/J
 % Fat
 Split by Sex
 (n=6;mean ± SEM;p≤0.05)



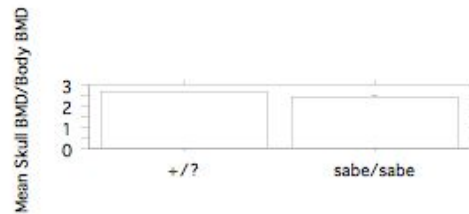4 Week B6(129P2)-*sabe*/J
 Skull BMD (g/cm2)
 Split by Sex
 (n=6;mean ± SEM;p≤0.05)



4 Week B6(129P2)-*sabe*/J
 Skull BMC (g)
 Split by Sex
 (n=6;mean ± SEM;p≤0.05)



4 Week B6(129P2)-*sabe*/J
 Skull BMD/Body BMD
 Split by Sex
 (n=6;mean ± SEM;p≤0.05)



sabe mice clearly exhibit the dwarfism that *Mmp14* mutants display. While not conclusive, *sabe* mice may have osteopenia as skull BMD was significantly less and whole body BMD was less but not significant.

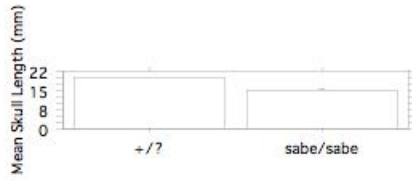B. Craniofacial Morphology Four-week-old *sabe/sabe* and +/- male skulls were collected and were prepared by incomplete maceration in potassium hydroxide, stained with alizarin red, and stored in undiluted glycerin (Green, 1952). Morphological measurements of the skull (table 2) were made using digital calipers (Stoelting, Wood Dale, Ill) with previously established landmarks².

Table 2: Digital Caliper Measurements and Calculated Ratios of four-week-old *sabe* Skulls stained with Alizarin Red (n=6; mean \pm SEM;^ap \leq 0.05)

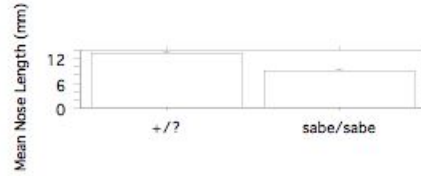
Measurements	Male <i>sabe/sabe</i>	Male +/-
Skull Length (mm)	15.16 \pm 0.032 ^a	19.86 \pm 0.291
Nose Length (mm)	9.01 \pm 0.215 ^a	13.19 \pm 0.292
Skull Height (mm)	8.60 \pm 0.147 ^a	10.03 \pm 0.214
Skull Width (mm)	9.31 \pm 0.180 ^a	10.02 \pm 0.127
Inner Canthal Distance (mm)	5.13 \pm 0.079	5.41 \pm 0.123
Upper Jaw Length (mm)	9.76 \pm 0.331 ^a	13.74 \pm 0.285
Lower Jaw Length (mm)	6.99 \pm 0.114 ^a	9.41 \pm 0.094
Jaw Length Ratio	1.39 \pm 0.035	1.46 \pm 0.017
Skull/Nose Length Ratio	1.68 \pm 0.025 ^a	1.51 \pm 0.014
Skull Height/Length Ratio	0.57 \pm 0.011 ^a	0.51 \pm 0.005
Skull Length/Width Ratio	1.63 \pm 0.016 ^a	1.98 \pm 0.022
Skull Height/Width Ratio	0.93 \pm 0.014 ^a	1.00 \pm 0.018
Ear Pinna Height (mm)	10.01 \pm 0.300 ^a	12.59 \pm 0.219

Mutants had significantly reduced skull length, nose length, skull height, skull width, lower and upper jaw lengths and ear pinna length than controls. The inner canthal of the mutants was not significant when compared to controls concluding that the overall reduced head size of mutants is not uniform (see graphs below). *sabe* mice have craniofacial dysmorphism as do *Mmp14* mice.

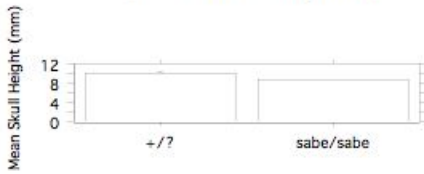4 Week B6(129P2)-*sabe*/J
Skull Length (mm)
Split by Sex
(n=6; mean \pm SEM; p \leq 0.05)



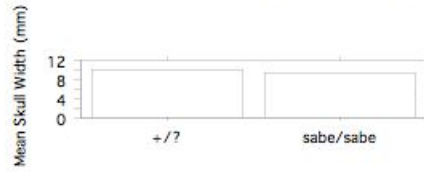
4 Week B6(129P2)-*sabe*/J
Nose Length (mm)
Split by Sex
(n=6; mean \pm SEM; p \leq 0.05)



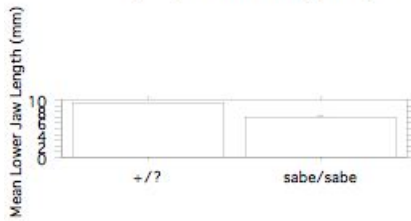4 Week B6(129P2)-*sabe*/J
Skull Height (mm)
Split by Sex
(n=6; mean \pm SEM; p \leq 0.05)




4 Week B6(129P2)-*sabe*/J
Skull Width (mm)
Split by Sex
(n=6; mean \pm SEM; p \leq 0.05)




4 Week B6(129P2)-*sabe*/J
Lower Jaw Length (mm)
Split by Sex
(n=6; mean \pm SEM; p \leq 0.05)




4 Week B6(129P2)-*sabe*/J
Upper Jaw Length (mm)
Split by Sex
(n=6; mean \pm SEM; p \leq 0.05)






4 Week B6(129P2)-*sabe*/J
Skull/Nose Length Ratio
Split by Sex
(n=6; mean \pm SEM; p \leq 0.05)



4 Week B6(129P2)-*sabe*/J
Skull Height/Length Ratio
Split by Sex
(n=6; mean \pm SEM; p \leq 0.05)





C. Eye Examination Three mutants and five controls were examined by a slit lamp and indirect ophthalmoscope at about one-month-old. Mutants have large optic nerves and controls were normal. Six mutants and three controls from the mapping cross were examined and again mutants had abnormal optic nerves with normal controls. However, the intraocular pressure in mutants and controls is normal. Some mice were examined again at two-months-old and the intraocular pressure was normal. One allele of *Mmp14*, *Mmp14*^{*tm1Hbh*} has been reported to have an abnormal orbital bone morphology. While still to be determined, the *sabe* phenotype may have shallow orbits therefore making the eyes protrude out as is consistently observed.

D. Hearing Tests One-month-old mice were assessed for hearing by auditory-evoked brainstem response (ABR). The two female and one male mutant all had severe hearing loss. One female and male control had normal hearing. One allele of *Mmp14*, *Mmp14*^{*tm1Hbh*}, has reported an abnormal ear phenotype, specifically an abnormal Meckel's cartilage morphology. We have yet to demonstrate if our ear phenotype is the same.

E. Pathology A pathological screen³ of a six-month-old mutant showed both temporomandibular joints had severe degeneration and fibrosis. Muscle fiber over both hips had ring fibers. These findings are similar to the fibrotic and arthritic characteristics of the *Mmp14* phenotype. Our *sabe* mutant also has what appeared to be a prolapsed vermis of the cerebellum. Mild hydrocephalus was also observed. Another nine-week-old mutant had a pointy looking cerebellum and long disorganized molars.

Discussion

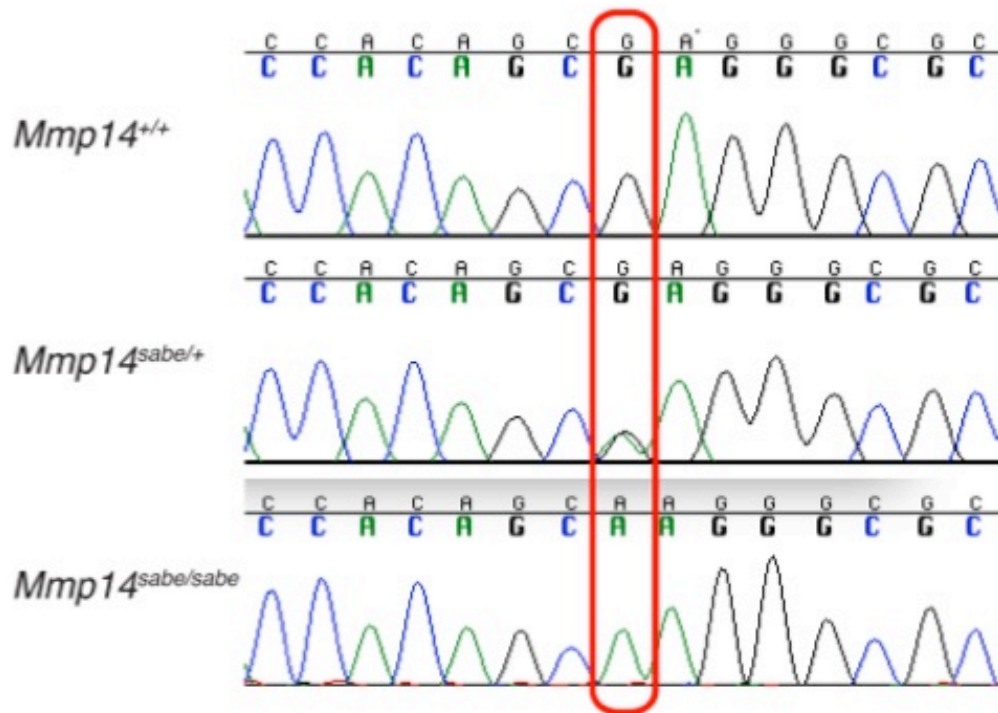
Mice carrying the *sabe* mutation mimic many of the characteristics of *Mmp14* null mice. *Mmp14* mice have a reported lung phenotype not observed in the *sabe* mutation. If *sabe* is a new allele of *Mmp14*, it would be the first spontaneous mutation in this gene.

Acknowledgements

We would like to thank: Connie Mahaffey for discovering the mutation; Norm Hawes for clinical eye evaluation; Chantal Longo-Guess for ABR results; Dr. Roderick Bronson, for pathological evaluation; Coleen Marden for preparation of tissues for histological assessment and for ovarian transplant surgeries.

Addendum November 2012

The *sabe* mutation was found to be a C to T transition in Chromosome 14 base pair 55,054,991 (NCBI Build 37), which is predicted to cause a substitution of a cysteine residue in place of an arginine at amino acid 91 in matrix metalloproteinase 14 (*Mmp14*).



Sequence chromatograms from control, heterozygous and homozygous *sabe* mutant mice. The base pair change results in a R91C mutation in the *Mmp14* protein. This mutation introduces an additional cysteine residue directly adjacent to a critical cysteine in the "cysteine switch" regulatory domain of *Mmp14*.

This is immediately adjacent to the critical cysteine residue of the cysteine rich domain. This differs from the point mutation in *Mmp14*^{m1Btlr}, which is an S442P in the hemopexin-like domain, yet there is no significant difference between their reported phenotypes.

Protocols

¹PIXImus Densitometry

PIXImus scans (PIXImus, LUNAR, Madison, WI) which provide skeletal and body composition data such as Bone Mineral Density (BMD, g/cm²), Bone Mineral Content (BMC, g/cm²), body mass (g), lean mass (g), fat mass (g), and % fat mass, are completed on groups of 6 male and 6 female 12 week old mutant and control mice. The skulls and bodies are scanned separately to provide independent data on skull BMD and BMC and body BMD and BMC. The PIXImus small animal densitometer (DEXA) has a resolution of 0.18 x 0.18 mm pixels and is equipped with software version 1.46 . The PIXImus is calibrated routinely with a phantom utilizing known values, and a quality assurance test is performed daily. The variability in precision for measuring total body BMD is, less than 1%, and approximately 1.5% for specialized regions such as the skull. The correlation between PIXImus BMD measurements of 614 lumbar vertebrae compared to peripheral quantitative computerized tomography (pQCT) measurements was found to be significant ($p < 0.001$; $r = .704$) (Donahue, 1999).

²Hand Caliper Skull Measurements

Seven measurements taken with hand held digital calipers are used routinely to define skull morphology at the Lab's craniofacial resource. These measures have a high degree of accuracy and precision in our hands and are able to discriminate differences between mutant and control skull characteristics. Our linear measures have been added to those illustrated by Dr. Joan Richtsmeier in her paper characterizing craniofacial differences in mouse models of Down Syndrome using three dimensional anatomical landmarks (Richtsmeier, 2000. Dev. Dyn. Feb; 217(2):137-45). Skulls are cleared with potassium hydroxide and stained with alizarin red dye in preparation for caliper measurements to be taken.

³Standard Histology Protocol used in the Mouse Mutant Resource

For fixation of tissues, mice were deeply anesthetized with tribromoethanol (avertin) until they no longer displayed a withdrawal reflex in the hind limbs and then perfused intracardially with Bouin's fixative following a flush of the vasculature with saline solution. After soaking in Bouin's for one week to demineralize bones, tissues were dissected. Six segments of spine with axial muscles and spinal cord in situ, representing cervical, thoracic and lumbar spinal segments, were dissected. The brain was removed and sliced into 6 cross sectional pieces at the levels of olfactory lobes, frontal cortex, striatum, thalamus, midbrain, rostral and caudal medulla with cerebellum. Midsagittal slices of hind leg through the knees were prepared. Slices of basal skull through the pituitary and inner ears were taken. Both eyes, salivary glands and submandibular lymph node, trachea plus thyroid and sometimes parathyroid were removed and cassetted. A longitudinal slice of skin from the back was removed. The thymus, slices of lung, and a longitudinal slice of heart were cassetted. Similarly slices of liver through gall bladder, kidney with adrenal attached, pancreas and spleen were prepared. The stomach was sliced longitudinally to include both squamous and glandular portions. Loops of small intestine from 3 levels and slices of large intestine and cecum were removed, as were slices of urinary bladder. The whole uterus, with ovaries attached, was taken. In males testes were sliced longitudinally. The accessory male organs including seminal vesicles, coagulating gland and prostate were removed en block. Altogether in most cases all tissue fit into a total of 10 cassettes. The cassettes were processed in an automatic tissue processor to dehydrate tissues which were then embedded in paraffin. Six micron sections were cut and stained with hematoxylin and eosin (H&E). Sections of brain and spinal cord in vertebral bones also were stained with luxol fast blue (LFB) for myelin and cresylecht violet (CV) for cellular detail.